

# Matrix Calculi in the Urinary Tract- A Prospective Cohort Study

NEEL SHAH<sup>1</sup>, MOHD HAMID SHAFIQUE AHMED<sup>2</sup>, SUNIL PATIL<sup>3</sup>, PRAKASH PAWAR<sup>4</sup>,  
JENI MATHEW<sup>5</sup>, AJIT SAWANT<sup>6</sup>, JITENDRA SAKHRANI<sup>7</sup>, VISHNU PRATAP<sup>8</sup>



## ABSTRACT

**Introduction:** Matrix calculi are infrequently encountered in the urinary tract. Their biochemical composition and unusual radiological appearance make it difficult to differentiate them from fungal balls or tumours of the urinary tract.

**Aim:** To study radiological, biochemical and microbiological characteristics of matrix calculi in the urinary tract and their management.

**Materials and Methods:** This prospective observational cohort study was conducted at a tertiary care hospital, from July 2016 to August 2019. Analysis of the clinical, radiological and biochemical profiles of patients who were found to have matrix renal or ureteric calculi was done. These patients underwent Percutaneous Nephrolithotomy (PCNL) or Ureteroscopic Lithotripsy (URSL) and the stone material evacuated was sent for analysis. Data was analysed using Microsoft Excel, version 2016.

**Results:** Matrix urinary stones were found in a total of 21 patients, out of which 15 were renal matrix calculi and six were

ureteric matrix calculi. Mean age of the patient population was 44.5 years. Male to female ratio was 1.33:1. Total 7 (33.3%) patients were found to have Chronic Kidney Disease (CKD). The mean radiodensity of all the stones was 403 Hounsfield Unit (HU). Six patients also had a concomitant crystalline calculus. Histopathological analysis of these matrix calculi revealed an amorphous lamellated appearance. The postoperative course of all the patients was uneventful. One patient presented with a non matrix stone in the opposite kidney after one year of follow-up.

**Conclusion:** Matrix calculi of the urinary tract are usually radiolucent on plane radiographs and have a low radiodensity on Computerised Tomography (CT) scan. Biochemical analysis of these calculi shows protein to be the predominant component. These calculi are more often seen in patients with Diabetes Mellitus (DM) or CKD and are frequently associated with a positive urine culture. They can be managed successfully with a combination of PCNL and URSL. Complete clearance is necessary to minimise recurrence.

**Keywords:** Hounsfield units, Percutaneous nephrolithotomy, Radiolucent stone, Ureteroscopic lithotripsy

## INTRODUCTION

Matrix calculi of the urinary tract are rare, with the literature consisting mainly of anecdotal case reports [1,2]. Boyce WH and Garvey FK reported that matrix stones are composed of two-thirds mucoprotein and one-third mucopolysaccharide by weight [3]. Due to the predominant composition of mucoproteins and mucopolysaccharides, these calculi are labelled as "fibromas, albumin calculi and colloid calculi" [4-6].

The high protein content and low calcium content cause these calculi to be radiolucent, making it difficult to detect them on plain radiograph [7]. Pure matrix calculi with no mineral content are too soft to produce acoustic shadowing making it difficult to detect them on ultrasound [8]. CT is a valuable tool for the evaluation of these calculi. Patients with matrix calculi may show a non enhancing soft tissue mass within the pelvicalyceal system on a CT scan [9]. Matrix calculi occupying the pelvicalyceal system or ureter may also appear as filling defects on imaging making it difficult to differentiate it from urothelial tumours or fungal ball in the urinary tract.

The clinical presentation of patients with matrix stones is similar to those of calciferous stones. Unusual presentations of acute renal failure due to bilateral renal matrix calculi and emphysematous pyelonephritis has also been described in literature [3,10]. Though open surgery was used in the past for treating matrix stones, endourological techniques have now replaced them [1,3]. Extracorporeal Shockwave Lithotripsy (ESWL) is not an effective option due to the gelatinous nature of these calculi and the lack of breakable mineral content [11]. Endourological procedures like PCNL and URSL are safe and efficacious for the management of matrix calculi in recent times [3,11-13].

Matrix calculus of the urinary tract is, thus, a rare and challenging clinical condition, with no clear recommendations for its management. The present study is based on the experiences from a high-volume tertiary care centre where matrix calculi of the urinary tract were diagnosed, radiological, biochemical and microbiological features were studied, and were successfully treated.

## MATERIALS AND METHODS

This was a prospective observational cohort study of patients undergoing endourological management for urinary stone disease, at a tertiary care centre in the Department of Urology, from July 2016 to August 2019. The study was approved by Institutional Ethics Committee (IEC) (07/2016-08/2019).

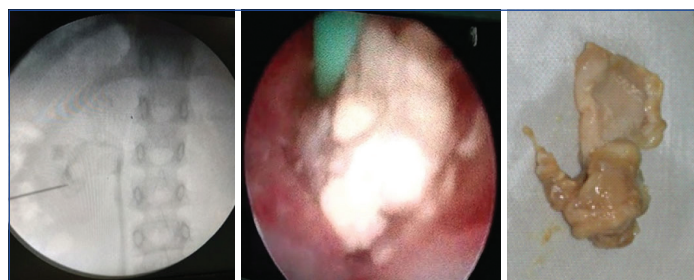
**Inclusion criteria:** All patients undergoing PCNL or URSL with intraoperative appearance and stone analysis consistent with matrix calculi were included in the study.

**Exclusion criteria:** Since the disease is rare with anecdotal cases, all patients of matrix calculi were included in the study. No patient was excluded.

## Study Procedure

Clinical, radiological and biochemical profiles of the patients were analysed. Patients with matrix calculi in the kidney underwent PCNL. After Retrograde Pyelogram (RGP), access was obtained through the appropriate calyx [Table/Fig-1] and dilated followed by placement of appropriate Amplatz sheath. Nephroscope was inserted and calculus visualised [Table/Fig-2]. The matrix calculi were removed using forceps. If any hard component was present, pneumatic lithotripsy was used to fragment it. In patients with matrix calculi in the ureter, semi-rigid ureteroscopy was done and matrix

stone components were removed using forceps [Table/Fig-3]. In all cases, complete clearance was ensured. All stones suspected of being matrix calculi were sent for analysis. All these patients were also followed-up for a minimum period of one year, after their surgery and stone clearance.



**[Table/Fig-1]:** Retrograde Pyelogram (RGP) showing the presence of a filling defect within the pelvicalyceal system, suggestive of a staghorn matrix calculus. **[Table/Fig-2]:** Nephroscopic appearance of matrix calculus. **[Table/Fig-3]:** Gross appearance of matrix calculus extracted by PCNL. (Images from left to right)

## STATISTICAL ANALYSIS

Data was analysed using Microsoft Excel, version 2016.

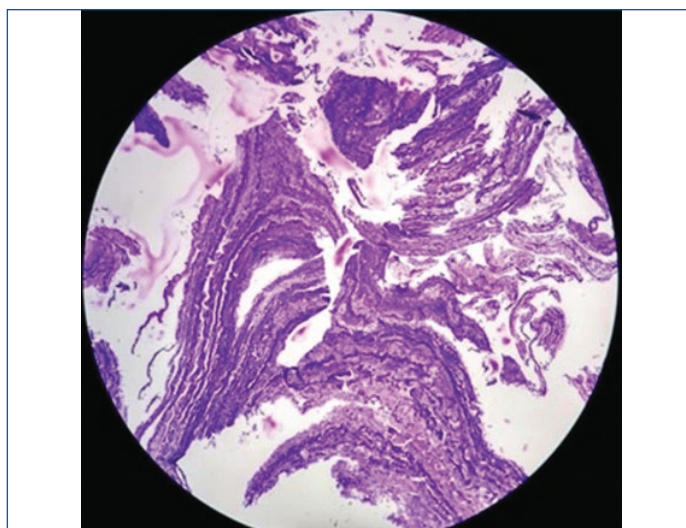
## RESULTS

During the study period, 625 PCNL and 462 URSL were done at our Institute. Of these 21 patients, were found to have matrix calculi- 15 out of 625 (2.4%) PCNL and 6 out of 462 (1.3%) URSL. Out of these 21 patients, 7 (33.33%) had CKD, while 8 (38.09%) suffered from DM. Mean radiodensity of all the stone was 403 HU range: (110-654). Fifteen patients (71.43%) had a positive growth on preoperative urine culture, which was treated with culture-specific antibiotics for atleast 48 hours prior to surgical procedure. Most commonly isolated organism was *E. coli* (42.86%), followed by *Proteus* (28.57%) [Table/Fig-4]. Stone culture was positive in 8 patients, with *E. coli* (62.5%) and *Proteus* (25%) seen most commonly. Six patients also had an associated crystalline calculus. Histopathological analysis (H&E, 40X) showed an amorphous lamellated appearance [Table/Fig-5]. On biochemical analysis of calculi, protein was found to be the predominant component in all cases.

Parameters	Study population (N=21)
Age (mean)	44.5 years
Male:Female	12:9 (1.33:1)
Radiodensity (mean, range)	403 HU (110-654)
<b>Co-morbidities</b>	
Chronic kidney disease	7/21 (33.33%)
Diabetes	8/21 (38.09%)
<b>Treatment given</b>	
PCNL	15/21 (71.42%)
URSL	6/21 (28.58%)
<b>Urine culture</b>	
Sterile	6/21 (28.57%)
<i>E. coli</i>	9/21 (42.86%)
<i>Proteus</i>	6/21 (28.57%)
Mean follow-up duration (months)	18.5 months
<b>Outcome</b>	
Stone free	20/21 (95.23%)
Recurrence (in opposite kidney)	1/21 (4.77%)

**[Table/Fig-4]:** Baseline demographic and treatment data.

The postoperative course of all patients was uneventful. The mean postoperative hospital stay was 2.1 days. One patient operated with PCNL for matrix calculus was detected with calcium oxalate monohydrate calculus on the opposite side after one year of follow-up, which was also managed with PCNL.



**[Table/Fig-5]:** Amorphous lamellated appearance seen on histopathological analysis (Haematoxylin and Eosin, 40X) of matrix calculus.

## DISCUSSION

Matrix stones in the urinary tract are rarely encountered in clinical practice. Only 2.4% of the patient population undergoing PCNL and 1.3% of those undergoing URSL in the present study over a period of three years were detected with matrix stones. Pure matrix stones are composed of more than 65% protein, unlike pure calcium stones where protein component was around 2.5% [2,3,14]. There has been some unresolved debate regarding the pathogenesis of matrix calculi. Boyce WH and Garvey FK have shown that the matrix component of crystalline calculi and non crystalline calculi are closely related, but not identical. The matrix substance is composed of two-third mucopolysaccharide and one third mucoprotein [3].

Urinary Tract Infection (UTI), caused by *E. coli* or *Proteus* organisms is a major risk factor for matrix calculi [2]. In the present study as well, 15 of 21 patients (71.43%) had a positive urine culture with either *E. coli* or *Proteus* organism. It has been hypothesised that, in patients with CKD and those having DM, proteinuria may contribute to an increased risk of matrix stone formation [3,5,10]. In the present study as well, diabetic and CKD patients comprised the predominant study population (71.43%). Matrix calculi can present as flank pain, UTI, acute renal failure due to ureteric obstruction and rarely as emphysematous pyelonephritis [2,10,15,16]. Though the presentation of the patients having matrix calculi is not very different from crystalline calculi, the radiological findings are different [3,7]. Matrix calculi may appear as radiolucent on a plain x-ray [8,17,18]. They may appear as filling defects on an Intravenous Pyelogram (IVP) or on a CT urography and the HU may vary depending on the composition or mineral content [5,8]. Though the history and imaging findings could raise suspicion, the conclusive diagnosis of matrix calculi can be made based on the intraoperative appearance and stone analysis findings. In the present study, biochemical analysis showed protein to be the predominant component of matrix stones and the amorphous lamellated appearance was observed on histopathological analysis. These findings aided in establishing the final diagnosis.

In the past, open surgical techniques were used for clearing matrix calculi [1]. However, in recent times, both antegrade and retrograde endourological techniques have been found to be safe and effective [1,10]. PCNL is the optimum treatment for a large (>2 cm) renal calculus, while semi-rigid or flexible uretero-roscope can be used for a ureteric or a small stone within the kidney. In the present study, all 21 patients were successfully managed by PCNL and URSL for stone clearance. Irrespective of approach, complete clearance is mandatory to prevent recurrence of such stones [11]. Any residual matrix calculus left, may harbour bacteria which can be responsible for recurrence.

## Limitation(s)

No long term follow-up of these patients was available. Also, the data of the present study was limited to that of a single centre. Larger, multicentric prospective studies with longer follow-up will help us understand this rare disease entity in a better manner.

## CONCLUSION(S)

The possibility of a matrix calculus should always be kept in mind in cases of radiolucent calculi and/or calculi having a low radiodensity on CT in patients with co-morbidities like DM, CKD. Biochemical analysis of these calculi shows protein to be the predominant component. These can be managed successfully with endourological techniques like PCNL and URSL. Complete stone clearance is to be ensured to prevent recurrence.

## REFERENCES

- [1] Stoller ML, Gupta M, Bolton D, Irby PB 3<sup>rd</sup>. Clinical correlates of the gross, radiographic, and histologic features of urinary matrix calculi. *J Endourol.* 1994;8(5):335-40.
- [2] Shah HN, Kharodawala S, Sodha HS, Khandkar AA, Hegde SS, Bansal MB. The management of renal matrix calculi: A single-centre experience over 5 years. *BJU International.* 2009;103(6):810-14.
- [3] Boyce WH, Garvey FK. The amount and nature of the organic matrix in urinary calculi: A review. *The Journal of Urology.* 1956;76(3):213-27.
- [4] Bani-Hani AH, Segura JW, Leroy AJ. Urinary matrix calculi: Our experience at a single institution. *J Urol.* 2005;173(1):120-23.
- [5] Liu CC, Li CC, Shih MC, Chou YH, Huang CH. Matrix stone. *Journal of Computer Assisted Tomography.* 2003;27(5):810-13.
- [6] Beltrami P, Ruggiera L, Guttilla A, Iannetti A, Zattoni F, Gigli F, et al. The endourological treatment of renal matrix stones. *Urol Int.* 2014;93(4):394-98.
- [7] Mall JC, Collins PA, Lyon ES. Matrix calculi. *The British Journal of Radiology.* 1975;48(574):807-10.
- [8] Sheppard PW, White FE. Demonstration of a matrix calculus using computed tomography. *The British Journal of Radiology.* 1987;60(718):1028-29.
- [9] Andrabi Y, Patino M, Das CJ, Eisner B, Sahani DV, Kambadakone A. Advances in CT imaging for urolithiasis. *Indian J Urol.* 2015;31(3):185-93.
- [10] Singh H, Pandey S, Dorairajan LN, Kumar S. Acute renal failure due to bilateral matrix renal calculi- A diagnostic dilemma. *International Urology and Nephrology.* 2001;33(2):311-13.
- [11] Chan CH, El-Hakim A, Andonian S. Renal matrix stone managed by ureteroscopic holmium laser lithotripsy. *The Canadian Journal of Urology.* 2010;17(2):5127-30.
- [12] Rowley MW, Faerber GJ, Wolf JS Jr. The University of Michigan experience with percutaneous nephrostolithotomy for urinary matrix calculi. *Urology.* 2008;72(1):61-64.
- [13] Lahyani M, Rhannam Y, Slaoui A, Touzani A, Karmouni T, Elkhader K. Bilateral kidney matrix stones: A rare case. *Pan Afr Med J.* 2016;25:102.
- [14] Allen TD, Spence HM. Matrix stones. *J Urol.* 1966;95(3):284-89.
- [15] Matthews LA, Spornak JP. A matrix calculus causing bilateral ureteral obstruction and acute renal failure. *J Urol.* 1995;154:1125.
- [16] Okochi H, Iiyama T, Kasahara K, Moriki T, Inoue K, Shuin T. Renal matrix stones in an emphysematous pyelonephritis. *Int J Urol.* 2005;12:1001-04.
- [17] Katsimantzas A, Zervopoulos G, Klapsis V, Pappadimitriou S, Foti L, Bouropoulos K, et al. A rare presentation of matrix stone and a short review of the literature. *Hellenic Urology.* 2018;30(2):3943.
- [18] Copley J, Phan YC, Mahmalji W. Matrix stone occupying an entire renal collecting system: A case report and video of diagnostic ureterorenoscopy. *Case Rep Urol.* 2018;2018:5892438.

### PARTICULARS OF CONTRIBUTORS:

1. Assistant Professor, Department of Urology, Lokmanya Tilak Municipal Medical College, Mumbai, Maharashtra, India.
2. Assistant Professor, Department of Urology, Lokmanya Tilak Municipal Medical College, Mumbai, Maharashtra, India.
3. Associate Professor, Department of Urology, Lokmanya Tilak Municipal Medical College, Mumbai, Maharashtra, India.
4. Professor, Department of Urology, Lokmanya Tilak Municipal Medical College, Mumbai, Maharashtra, India.
5. Senior Resident, Department of Urology, Lokmanya Tilak Municipal Medical College, Mumbai, Maharashtra, India.
6. Professor and Head, Department of Urology, Lokmanya Tilak Municipal Medical College, Mumbai, Maharashtra, India.
7. Assistant Professor, Department of Urology, Lokmanya Tilak Municipal Medical College, Mumbai, Maharashtra, India.
8. Senior Resident, Department of Urology, Lokmanya Tilak Municipal Medical College, Mumbai, Maharashtra, India.

### NAME, ADDRESS, E-MAIL ID OF THE CORRESPONDING AUTHOR:

Dr. Prakash Pawar,  
Professor, Department of Urology, Lokmanya Tilak Municipal Medical College,  
Mumbai-400022, Maharashtra, India.  
E-mail: praxpawar@gmail.com

### PLAGIARISM CHECKING METHODS: [Jain H et al.]

- Plagiarism X-checker: Dec 10, 2021
- Manual Googling: Jan 05, 2022
- iThenticate Software: Feb 09, 2022 (7%)

### ETYMOLOGY: Author Origin

### AUTHOR DECLARATION:

- Financial or Other Competing Interests: None
- Was Ethics Committee Approval Obtained for this study? Yes
- Was informed consent obtained from the subjects involved in the study? Yes
- For any images presented appropriate consent has been obtained from the subjects. Yes

Date of Submission: **Dec 07, 2021**  
Date of Peer Review: **Dec 21, 2021**  
Date of Acceptance: **Jan 21, 2022**  
Online Ahead of Print: **Feb 12, 2022**  
Date of Publishing: **Apr 01, 2022**